

Operative Details :-

13/07/2012

→ ~~open~~ ^{closed} intramedullary titanium elastic nailing done @ Claude ↓ GA

→ closed reduction in term of fixation of medial malleolus done & 4mm cannulated cancellous screws done.

→ procedure → uneventful.

Treatment given/Advised

→ ~~75~~ ⁷⁸ chymoral forte (100)

→ ~~75~~ ⁷⁸ eibility (100)

→ ~~75~~ ⁷⁸ paraspod D (100)

→ ~~75~~ ⁷⁸ (get ok) (070)

→ ~~75~~ ⁷⁸ xoxe-evsary (177)

Treatment Advised :-
x10 sleep/rel

ad

17

rel

1.

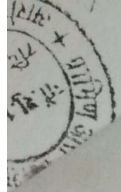
Prognosis and Instructions

→ Review after 10 days for Physiotherapy

4 Dressing


→ Advised Elevation of limb Movement Analgesic
→ Finger

→ Condition of the limb of discharge
→ Stable



Dr. UMESH JAYTODI
M.B.B.S.D.Ortho
CONSULTANT ORTHOPAEDICS SUP.
Reg. No. - 2452

Name of Consultant
& Signature



17872

17 JUL 2017
~~18 JUL 2017~~

mlc 346
12/17/17 at
11am

inf^{ad} mo / mtd

SIBIMO

BP 110/70 mmHg
clia. RTA today

GR mod.
- small scratches on occipital & lower limbs
ragged

GR mod.

Afubom

vipud shu

SF, HR

- By c & d done
- inj T.T. 0.5 ml i.m.
- inj PR core i.m.
- T: DTR 10 IBO
- T: PR 10 IBO
- Rap amon ITRs
- Betadine ointment

2/17/17
- 2/17/17

3/10 marks

small
* 3 marks over ant abdominal wall above umbilicus.